

# Image Processing in Retinal Angiography: Extracting Angiographical Features without the Requirement of Contrast Agents

Tati Rajab Mengko, Astri Handayani, Vanya Vabrina Valindria, Samekta Hadi, Iwan Sovani  
Biomedical Engineering Research Division, School of Electrical Engineering & Informatics  
Bandung Institute of Technology, Jl. Ganesa 10 Bandung 40132 Indonesia  
Email: [astri@biomed.ee.itb.ac.id](mailto:astri@biomed.ee.itb.ac.id)

## Abstract

*Imaging of retinal blood vessels performed by fundus fluorescence angiography (FFA) requires the use of injected fluorescence agent to enhance blood contrast during image acquisition. This procedure leads to several risks to the patient, including nausea and loss of consciousness. Another available approach which applies no contrast agent is the fundus autofluorescence imaging (FAF). However, the natural characteristics of images produced from the FAF procedure is blurred, and the contrast of the image is narrowly-spanned such that important retinal features are sometimes indiscernable. This paper proposes alternative methods to obtain the angiographical information from standard colour-fundus images and FAF images, instead of the conventional FFA images, thus minimizing the risk to the patient by eliminating the need for fluorescence contrast agent.*

## 1. Introduction

Retinal imaging plays an important role on the diagnosis of abnormalities and diseases of the retina. The retina anatomical position which is situated behind the eye lens makes its observation becomes difficult without the assistance of specific imaging modality. Fundus camera is the most common imaging modality used for retinal imaging. There are several image acquisition procedures developed based on fundus camera, each of which aims to detect particular features of the retina.

Some of image acquisition procedures widely recognized in fundus photography are standard colour-fundus photography, Indocyanine Green (ICG) fundus photography, Fundus Fluorescence Angiography (FFA), and Fundus Autofluorescence (FAF) photography. The differences between these procedures basically lie on the wavelength used in the imaging process and the treatment given to the patient prior to the imaging procedure.

One of the most prominent objects of interest appears in retinal images is the blood vessel vasculature and its pathological complications, e.g. aneurysm, leakage and neo-vascularization. The use of injected contrast agents has its own drawbacks. Beside being a costly procedure, it is also tightly associated with nausea and loss of consciousness. Not to mention that the clarity of the features of interest relies on the appropriate timing of image acquisition, which depends on the amount of time required for a proper uptake of the injected agent by the blood flow - a parameter which may vary within individuals.

As an alternative to imaging procedures requiring injection of contrast agents, the Fundus Autofluorescence imaging (FAF) is developed. The FAF utilizes the natural fluorescence property of the blood which appear under the illumination of the imaging wavelength of 488 nm. The most common range of wavelength used in FAF is 475-515 nm. One major problem arises in the FAF procedures is that within the range of wavelength used, the blood is not the only object in the retina which emit fluorescence. Therefore, although the FAF procedure is able to capture the image of blood vessel vasculature, the visual appearance of this feature is not adequately apparent and distinctive for diagnostic purposes.

Refinement has been invented to overcome the inherent problem of the FAF procedure, that is the use of the confocal laser scanning ophthalmoscope (cSLO) instead of common fundus camera to conduct the autofluorescence imaging. The confocal set-up of the cSLO prevent the device from capturing the image of fluorescing objects other than the blood. However, since cSLO is a highly complex and costly optical system, it is not as widely available as the standard fundus camera.

This paper proposes alternative methods to obtain a proper visualization of the clinically crucial angiographical information; with the most common imaging device available and without requiring the risky injection of contrast agents. The proposed methods are based on digital image processing techniques, since most fundus cameras produce digital output and is equipped with PC interface. There are two image processing approaches presented in this paper, they are the image enhancement of standard colour-fundus images and the image restoration of FAF images with reference to the cSLO images.

## 2. Image Enhancement of Standard Colour-Fundus Image

The standard colour fundus images used in the proposed system are of 24-bit RGB (red, green, and blue intensity channel), with the original size of 2588x1958 pixels. Prior to the enhancement process, the input image is downsampled by two to reduce computation time. The downsampling factor of two is determined under the ophthalmologist consent, with respect to the preservation of information exists in standard colour-fundus images. The image enhancement modules altogether provide detection of blood vessel leakage and macular edema in the retina, which are commonly found in diabetic retinopathy.

## 2.1. Blood vessel structure enhancement module

The blood vessel structure enhancement module extracts the blood vessel vasculature from a normalized green channel input image using wavelet-gabor multiresolution filters. It captures the blood vessel anatomical structure from the coarsest to the finest scale, and reveals abnormalities reside within this pattern. The use of green channel intensity in the enhancement main processes are based on the fact that green channel intensity provides the most distinctive representation of blood within the retina, compared to the red and blue channels [12].

An obstacle in efforts for automated identification of angiographical structures in colour-fundus images is the wide range of fundus image intensity variability in different patients/subjects. These variations are strongly correlated to skin pigmentation and iris colour. We apply a colour normalization method to make the images invariant with respect to this variation. Later, an intensity reversal is conducted to obtain a visual appearance which is similar to the FFA image.

The wavelet-gabor multiresolution filters [8] is chosen because of its capability of tuning to specific frequencies, allowing it to be adjusted for blood vessel enhancement and noise filtering in a single step. In addition, it also captures leakage texture, which is characterized by smoother area without much intensity variation.

The basis function of the wavelet-gabor in this case is defined as :

$$\psi_G(x, y) = \frac{1}{2\pi s \sigma_x \sigma_y} \exp \left[ -\frac{1}{2} \left( \frac{x^2}{\sigma_x^2} + \frac{y^2}{\sigma_y^2} \right) \right] \exp (if_{01}x + if_{02}y) \quad (1)$$

Here,  $f_{01}$  and  $f_{02}$  defines the frequency of the complex exponential in the x and y axis respectively, while  $s$  denotes the scale of the multiresolution filters. We have set  $f_{01} = 0$  and  $f_{02} = 3$ . This characteristic has been chosen in order to enable the transform to present stronger responses for pixels associated with the blood vessels. The Gabor 2-D wavelet transformation is implemented as the inner product of input image and conjugate basis function  $\psi_G^*$  in frequency domain.

$$T(s) = f(\omega_1, \omega_2) \cdot \psi_G^*(\omega_1, \omega_2) \quad (2)$$

The result of the blood vessel structure enhancement module is given in Figure 1.

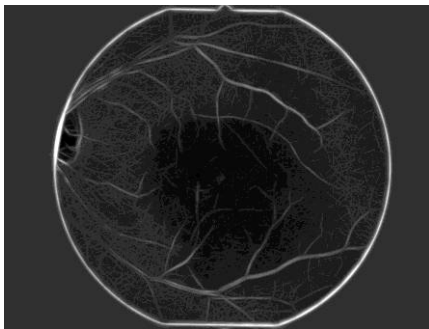

Figure 1 Enhancement of Blood Vessel Structure

## 2.2. Blood vessel leakage area enhancement module

The leakage area enhancement module aims to produce an image visualization which is similar to the FFA appearance of blood vessel leakage in the retina, based on the previously enhanced blood vessel visualization in the first module and a normalized green channel intensity image. It is basically an Artificial Neural Network (ANN) classifier which is trained to perform a pixel-to-pixel intensity mapping between its input images and a reference FFA image. The output of the classifier bears a visual resemblance to the standard FFA image, thus is familiar to the ophthalmologist for diagnostic purposes.

The use of ANN-based pixel-to-pixel intensity mapping in the retinal blood vessel leakage enhancement module is laid on the premises that the area of a blood vessel leakage in a retinal image should be related to the location of a blood vessel - as a physical source of the leakage-, and a more prominent representation in some degree of blood-like intensity within the vicinity. ANN is used to acquire an appropriate weighting between this two factors in contributing to the appearance of a blood vessel leakage in the retina.

In order to lower the false-positive probability of the pixel-to-pixel intensity mapping function performed by the ANN, optic disc as an area of the retina which intensity is close to the blood are detected and eliminated from the green channel image prior to ANN classification. This preprocessing step is conducted with morphological operation. The final result of the blood vessel leakage area enhancement module is shown in Figure 2.

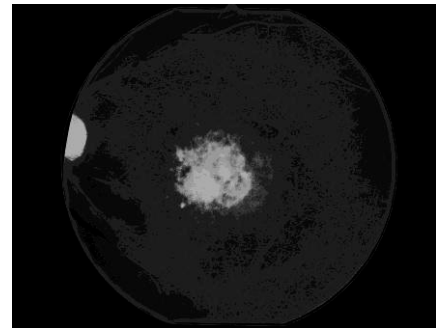
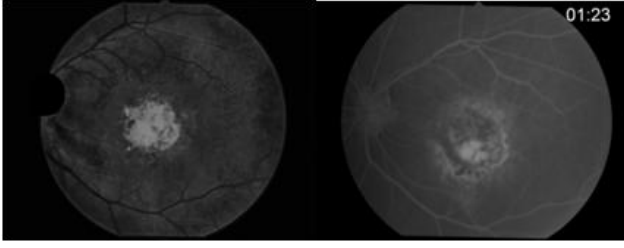


Figure 2 Enhancement Result of Blood Vessel Leakage Area (ANN Image)

## 2.3. Overall contrast enhancement module

The contrast enhancement module utilizes the Contrast-limited Adaptive Histogram Equalization (CLAHE) method with the specification of 8x8 neighbourhood windowing and bottom 5% histogram clipping limit. The CLAHE image is combined with the image obtained from ANN blood vessel leakage area detection module by weighted addition. By this combination, over-exposure in optic disk area can be reduced, the leakage area which appears in those two images is strengthened, and blood vessels appears darker than the leakage area. These three features altogether provides more accurate description of blood vessel structure and its leakage area. The final result of this module compared to the FFA reference image is given in Figure 3.



**Figure 3 Contrast-enhanced image (left) and FFA reference image (right)**

### 3. Image Restoration of Fundus Autofluorescence Image

The fundus autofluorescence images used in the proposed system are of 8-bit grayscale and 2588x1958 pixels, downsampled with the factor of two. The images were obtained with a standard fundus camera image operating in the IR mode, with the imaging wavelength range of 475-515 nm and barrier filter set at 530 nm.

The fundus autofluorescence image restoration aims to obtain the appropriate visualization of angiographical features with reference to the confocal laser scanning ophthalmoscope gold-standard image. It focuses on the observation of the macula area, especially on the pigmentation of the retinal epithelium. This feature relates to the Age-related Macular Degeneration (AMD) and Stargardt's disease. Hyperfluorescence is associated with the early stage of photoreceptor degeneration in the retina, while hypofluorescence is associated with the loss of retinal epithelium, indicating a chronic loss of photoreceptors.

#### 3.1. Image preprocessing

The image preprocessing step is basically a contrast enhancement using histogram specification. The reference image for histogram specification is the cSLO image. The intensity normalization is necessary since the inherent problem of the fundus autofluorescence image is narrow range of intensity and blur. The narrow range of intensity is caused by the nature of the fundus camera when is set in the IR operation modes, while the blur is brought by the interference of different level of fluorescence emitted by various object in the retina, under the illumination of the wavelength range used.

#### 3.2. PSF Estimation

The image processing of the FAF image is modeled as a restoration process of an image with linear shift-invariant degradation function, thus can be represented by the convolution/deconvolution operator. It is assumed that the function  $h(x,y)$  which cause the degradation of the original image  $f(x,y)$  is a linear shift-invariant point-spread function (PSF).

$$g(x, y) = f(x, y) \otimes h(x, y) + n(x, y) \quad (3)$$

SeDDaRA [5] models the PSF in the frequency domain as a real-valued function  $H(u,v)$ . This PSF is required to have the form:

$$H(u, v) = K_G S \left\{ \left| G(u, v) - N(u, v) \right| \right\}^{\alpha(u, v)} \quad (4)$$

where  $G(u,v)$  is the frequency domain representation of the input image,  $N(u,v)$  is the additive noise (if present),  $\alpha(u,v)$  is a tuning parameter and  $K_G$  is a real, positive scalar constant to ensure that  $|H(u,v)| \leq 1$ .  $S\{\}$  is a smoothing operator, in this case a 3x3 averaging filter.  $\alpha(u,v)$  can be either frequency-dependent or independent. In the frequency independent case,  $\alpha(u,v)$  should be a positive scalar between 0 and 1. In the frequency dependent case,  $\alpha(u,v)$  is determined with the following equation:

$$\alpha(u, v) = \frac{\ln \left[ K_G S \left\{ G(u, v) \right\} \right] - \ln \left[ K_F S \left\{ F'(u, v) \right\} \right]}{\ln \left[ K_G S \left\{ G(u, v) \right\} \right]} \quad (5)$$

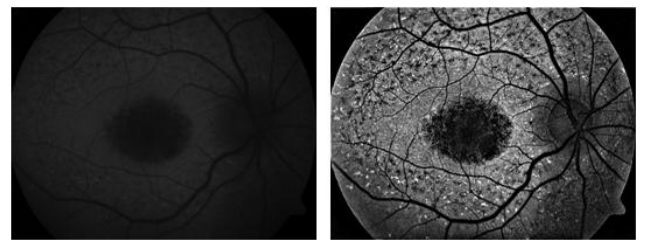
where  $F'(u,v)$  is the frequency domain representation of the reference image and  $K_F$  is a real positive scalar constant. The reference  $F'(u,v)$  should be similar to the the real image in term of frequency component distribution. In our case, we use a frequency domain representation of a confocal laser scanning ophthalmoscope image as the reference.

#### 3.3. Image deconvolution

The obtained PSF estimation is then used to restore the FAF image through deconvolution operation. The formulation of SeDDaRA requires the frequency domain representation of the input and reference image to fit a 2-dimensional Gaussian distribution. It also assumes the PSF as a Gaussian-distributed 2-dimensional function. The deconvolution is conducted with pseudo-inverse method, which formula in the frequency domain is given below:

$$\hat{F}(u, v) = \frac{H(u, v) \otimes G(u, v)}{|H(u, v)|^2 + \delta} \quad (6)$$

Here,  $\delta$  is a positive scalar constant to prevent division by zero. In this case, the chosen value for  $\delta$  is 0.001. The restored image is obtained by performing an inverse Fourier transform operation to the result of the last equation. The overall result of this procedure is given in Figure 4.



**Figure 4 Image before (left) and after restoration (right)**

## 4. Results

### 4.1. Image enhancement of the standard colour-fundus image

This system is evaluated on 42 standard colour-fundus images assessed by four ophthalmologists with retinal disorders specialization. Output images and FFA reference images are compared to see their correspondence of

retinal leakage area. The assessment level is given in the scale from 0 to 5. When all of the leakage area are wrongly detected, they are given the point of 0. The maximum point of 5 means that all of the leakage area in the output image was correctly in accordance with the reference image.

The average assessment score is 3,5 from the maximum score of 5. Therefore, this system demonstrated 70% correspondence with the reference images. Failure occurs since this system cannot differentiate the leakage source and the macula edema (excess fluid in the macula area caused by the nearby blood vessels leakage). It is a feature that can only discerned by time-series observation of contrast agent uptake by the blood flow in the retina.

#### 4.2. Image Restoration of the Fundus Autofluorescence Image

This system is evaluated on 15 fundus autofluorescence images, tested by 3 ophthalmologist specializing in retinal disorders. The subjective assessment level is also given in the scale of 0 to 5. The score of 0 means the image is really inadequate for diagnostics and 5 means it is perfectly supportive for diagnostics, in term of the pigmentation appearance of the macula.

The average assesment score given by the three ophthalmologists is 4, meaning that although the restored image is not perfect for diagnosis, it is considered adequate at least for preliminary screening of pigmentation abnormalities in the macula. The imperfection in results observed by the ophthalmologists is brought by the extremely sharp appearance in the edges of high-contrast blood vessel vasculature, probably caused by an extent of ringing effect commonly occurs in inverse filtering approaches. However, since the focus of observation in this case is the macular pigmentation, this unnatural appearance of blood vessel does not directly contribute to the diagnosis.

### 5. Conclusion and Further Works

The results obtained indicate that the standard colour-fundus image enhancement system could be successfully applied for the detection of blood vessels leakage in images of the retina, without requiring contrast agent injection to patients. The wavelet-gabor multiresolution filters and ANN classification can help to retrieve the information of retina blood vessel vasculature together with its leakage area. Further work needs to be focused on the further characterize leakage source and edema area, also to analyze the edema area accurately.

The results obtained in the fundus autofluorescence image restoration needs more validation in aspects of degradation process modeling as well as PSF modeling. Refinement in deconvolution approach is considered necessary to obtain better future results, especially in the visualization of blood vessel vasculature. However, in highlighting the macular pigmentation, the system has achieved adequate result to support diagnosis.

One obstacles arises in the clinical implementation of both the enhancement and restoration systems being proposed is the large number of parameters required to fine-tune the system. Further works should be addressed to find a mechanism to automatically set the appropriate value of these parameters.

### References

- [1] **M. Hammer, et.al.** *Ocular fundus autofluorescence observations at different wavelengths in patients with age-related makular degeneration and diabetic retinopathy*: Springer-Verlag, 2007.
- [3] **R.F. Spaide.** *Fundus Autofluorescence and Age-related Makular Degeneration*: Elsevier Science, 2003.
- [4] **S. Yang, et.al.** "Image restoration with high resolution adaptive optical imaging system". *IEEE Symposium on Computer-Based Medical Systems (CBMS'04)*, 2004.
- [5] **J. N. Caron, N.M. Namazi, and C.J. Rollins.** "Noniterative blind data restoration by use of an extracted filter function". *Applied Optics* 2002(41).
- [6] **J.N. Caron.** *Signal Processing Using The Self Deconvolving Data Reconstruction Algorithm*. 6,859,564 B2 United States Patent, 2005.
- [7] **D. Kundur and D. Hatzinakos.** "Blind Image Deconvolution". *IEEE Signal Processing Magazine*, pp.43-63, May, 2006.
- [8] **J.V.B. Soares, J.J.G. Leandro, and R.M. Cesar-Jr.** "Retinal Vessel Segmentation Using the 2-D Gabor Wavelet and Supervised Classification," *IEEE Transaction on Medical Imaging*, vol. 25, September, 2006.
- [9] **P. Bhattacharya, Q. Li, and L. Zhang.** "Automated Retinal Vessel Segmentation Using Multiscale Analysis and Adaptive Thresholding," *IEEE Southwest Symposium on Image Analysis and Interpretation*, pp.139 – 143, 2006.
- [10] **Q. Li, et.al.**, "A New Approach to Automated Retinal Vessel Segmentation Using Multiscale Analysis," *The 18th International Conference on Pattern Recognition (ICPR'06)*, 2006.
- [11] **R.M Rangayyan, F. Olomi, and F.J. Ayres,** "Detection of Blood Vessels in the Retina Using Gabor Filters," *Canadian Conference on Electrical and Computer Engineering (CCECE 2007)*, vol.22, pp.717 – 720, April 2007.
- [12] **A. Osareh,** *Automated Identification of Diabetic Retinal Exudates and the Optic Disc*, University of Bristol, January 2004.
- [13] **S. Mallat,** "A Theory for Multiresolution Signal Decomposition : The Wavelet Representation," *IEEE Transaction.*, PAMI-11 : 674 – 693, 1989.
- [14] **F.G. Holz, R.F. Spaide.** *Medical Retina.*: Springer-Verlag Berlin Heidelberg, 2007.
- [15] **R.A. Simandjuntak, A.B. Suksmo, T.R. Mengko. I. Sovani,** "Computer-aided Diagnosis of Microaneurysm to Support Diabetic Retinopathy Screening". *Health-comm Conference*, 2006.